

Use of a Novel Fibrin Dressing on Spinal Cerebrospinal Fluid Leaks

Charles T Floyd MD; Rudolfo A Padua PhD; Curtis E Olson PhD

St. Teresa Medical, Inc., Eagan, MN

Introduction

A novel fibrin dressing (NFD) is a highly efficacious hemostatic agent in vascular, solid organ and bone bleeding. The safety and performance of the NFD to provide a watertight seal of the dura in a caprine spinal CSF leak model was examined in the present study.

Methods

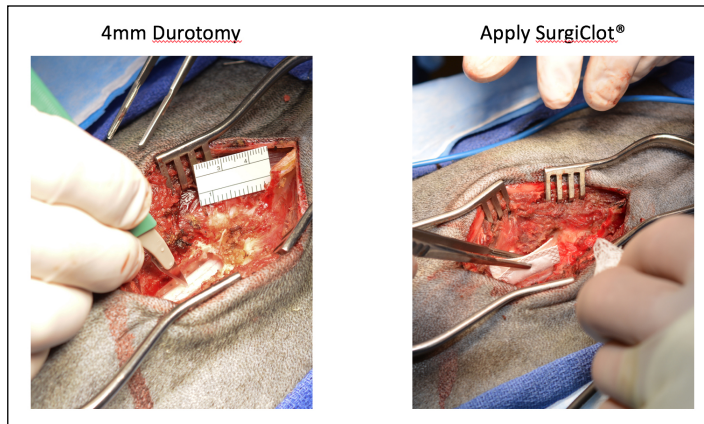
After lumbar laminectomy the dura was incised 4-5mm with a #11 scalpel. CSF leakage was confirmed by direct visualization and by Valsalva maneuver (20cm water for 10 sec). A NFD dressing designed for intraspinal use was applied with pledget providing slight pressure for 2 minutes. After a total of 5 minutes the pledget was removed and a Valsalva maneuver was performed. If leakage occurred the procedure was repeated. If leakage continued, the durotomy was closed with a running silk suture.

The goats were survived for 30 days and then euthanized. The wound was inspected for the presence of a pseudomeningocele. The thecal sac was injected with methylene blue to a pressure of 200cm while the durotomy site was observed. The entire thecal sac and contents was then removed and processed for histopathological examination.

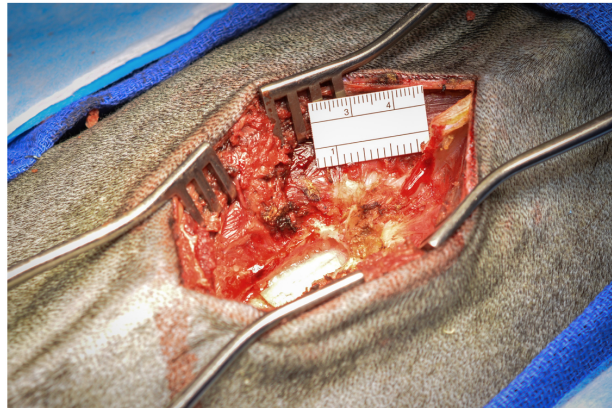
Results

The durotomies of 4/5 goats were sealed after initial application of one or two NFD dressings. A fifth goat continued to leak CSF with Valsalva maneuver following the second NFD dressing and required suture repair. In this particular animal, the NFD adhered to the pledget rather than to the dura, so it did not remain in situ.

None of the five goats had developed a pseudo-meningocele. All five goats had developed normal fibrosis at the surgery site based on gross observation. All five of the repairs withstood pressure of greater than 200cm without leakage. Histopathology confirmed the presence of normal fibrosis with minimal inflammatory reaction. Minimal giant cell macrophages were observed and we saw no residual foreign body material.

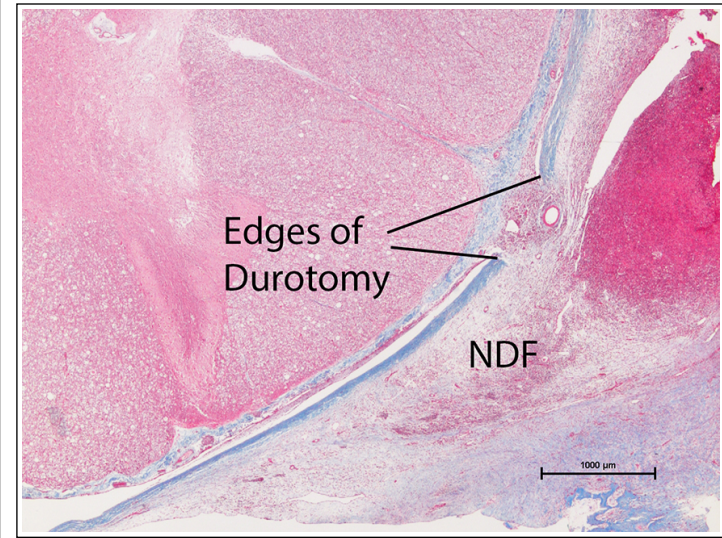


CSF leak controlled, Valsalva



Conclusions

The NFD sealed 80% of the dural injuries. We observed no leakage of CSF either spontaneously or with Valsalva pressures and this appeared to be a permanent repair after 30 days. The dressing generally is more adherent to tissue than to gauze and is simple to use with no preparation necessary. Our pre-clinical studies show that this dressing controls CSF leaks from cranial and spinal dura and is useful as an autonomous, translucent patch that adheres tenaciously to the dura, allowing the surgeon to continue to work with impunity from dislodgement and recurrent leak. We believe the NFD will be an important tool to control CSF leak for spinal surgery.



Learning Objectives

A fibrin dressing that leaves no residual material is effective at sealing spinal durotomies.

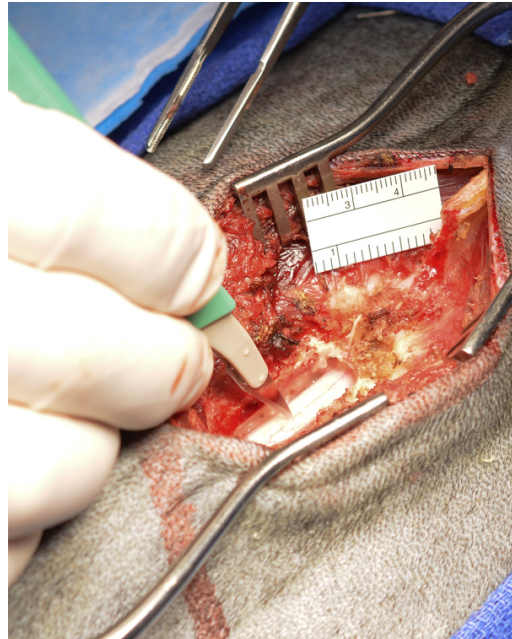
References

Floyd CT, Rothwell SW, Martin R, Risdahl J, Olson CE. A salmon thrombin-fibrinogen dressing controls hemorrhage in a swine model compared to standard kaolin-coated gauze. *Journal of Special Operations Medicine*, 12(1): 49-55, 2012.

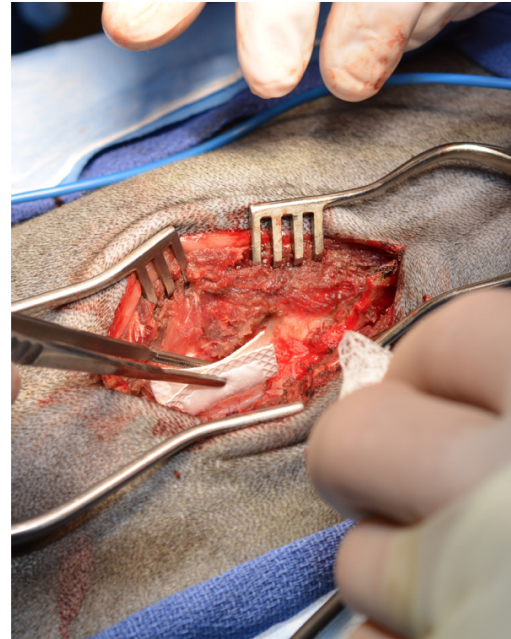
Floyd CT, Rothwell SW, Risdahl J, Martin R, Olson C, Rose N. Salmon thrombin-fibrinogen dressing allows greater survival and preserves distal blood flow compared to standard kaolin gauze in coagulopathic swine with a standardized lethal femoral artery injury. *Journal of Special Operations Medicine*, 12(2): 16-26, 2012.

Floyd CT, Padua RA, Olson CE. Hemostasis and safety of a novel fibrin dressing versus standard gauze in bleeding cancellous bone in a caprine spine surgery model. *Spine Deformity*, Accepted with publication pending.

4mm Durotomy



Apply SurgiClot®



CSF leak controlled, Valsalva

